

Suspected Pseudohermaphroditism in a Wild Asian Elephant

N. Kalaiivanan¹, R. Venkataramanan^{2*}, C. Sreekumar², N. Murali³ and R. K. Srivastava¹

¹Forest Department Mudumalai Tiger Reserve, Nilgiris, Tamil Nadu, India

²Tamil Nadu Veterinary and Animal Sciences University, Sandynallah, Nilgiris, Tamil Nadu, India

³Mecheri Sheep Research Station, Pottaneri Salem, India

*Corresponding author's e-mail: venkyvet@gmail.com

Introduction

Asian elephants are sexually dimorphic in size with males being much larger. Elephants have intra-abdominal testes and sex assignment has to rely on external characters. Only males bear tusks in Asian elephants. Adult bulls exhibit distinct secondary sexual characters such as a penile bulge (a tubular prominence along the perineum), a prominent nasal protuberance also termed as forehead bump (Chandrasekharan 2003) and broad base of trunk, which differentiate them from adult cows. The male has no scrotum, and the female has a hypertrophied clitoris that resembles the male's penis, except that it is smaller and not canalized by the urethra and cannot be extruded (Glickman *et al.* 2005). The ano-genital distance as measured from the edge of the anus to the edge of the genital opening in male and female elephants are different with it being longer in males. It is difficult to sex immature elephants from the appearance of external genitalia. Adult Asian elephant females and their young of both sexes form matriarchal groups, with pubertal males dispersing from natal groups (Sukumar 1989; Desai & Johnsingh 1995).

The present paper describes a suspected case of pseudohermaphroditism in a wild Asian elephant. A search of literature revealed an absence of previous reports of such an occurrence.

Methods

A lone wild elephant about 2 m in height (possibly around 6 years of age) with tusks about 33 cm was involved in confrontations with humans at Coonoor Range in the Nilgiri Biosphere Reserve.

It chased workers in tea plantations and damaged crops and human property. Coonoor range is not a recognised elephant habitat. The region is highly fragmented with sparse patches of forest among extensive tea plantations and human habitation. Therefore it was decided to relocate the animal to Mudumalai Tiger Reserve, which is a large contiguous forest with fewer disturbances from human beings, 54 km from Coonoor range.

The Forest Veterinarian, Mudumalai Tiger Reserve (senior author), was called upon to capture and translocate the animal. The animal was darted using a Dist-Inject dart gun with 150 mg xylazine. During xylazine anaesthesia, there was no relaxation and extrusion of the penis, which led to doubts regarding the sex of the animal. The elephant was restrained with the help of kumkies (trained captive elephants) and a thorough examination of the location and appearance of genitalia was carried out (Fig. 1). Blood was collected from the ear vein in heparinised vacutainers. The animal was



Figure 1. The wild 'tusker' after restraint using kumkhi elephants (note the length of tusks which are proportionately longer than 'tushes').

subsequently relocated to Mudumalai Tiger Reserve.

Blood was sent to the Veterinary College and Research Institute, Namakkal for karyotyping, to determine the genetic sex. Leucocyte cultures were set up in RPMI 1640 culture medium (8 ml) with Pokeweed (0.1 ml) as mitogen. Autologous plasma (1.5 ml) and buffy coat (0.2 ml) from the centrifuged sample were added to cultures. The cultures were incubated at 37°C for 3 cell cycles (72 h). One and half hours prior to harvest, 0.01% colchicine was added to the cultures and incubation was continued. The cultures were subjected to hypotonic treatment (0.075 M KCl) and fixed in Cornoy's fixative (methanol - 3 parts: acetic acid - 1 part). The slides were prepared and stained with 4% Giemsa. Non-overlapping metaphase spreads with full chromosome (2n) complement were chosen and examined using a Leica model DM 2500 microscope at 1000 x magnification. Over 50 metaphase spreads were examined for any numerical / structural chromosome alterations (Halnan 1977).

Results and discussion

The animal concerned was a tusker (each tusk measuring around 33 cm in length), and presence of a penile bulge, prepuce sheath and frontal bump were other masculine features noticed (Fig. 2). However, unlike normal bull elephants, the frontal bump was less pronounced, penile cord was less prominent and penis was replaced by a small protrusion (about 2 cm long), which was smaller than even the hypertrophied clitoris seen in females. A ballooning of skin just above the prepuce opening was noticed.

In the normal male, during urination, the protruded penis is directed backwards and urine is forced out in an oblique direction from the tip of the penis. However, in this animal, the urine was found to fall straight to the ground from all over the genitalia and not from the tip of the projection.

The ballooning could possibly be due to hypospadiac (irregular placement of the male

urethral meatus, which is usually found at the tip of penis) condition, wherein the urethra does not extend to the tip of the penis. The muscles at the commissures of tusk were not well developed and the general appearance of the animal was unlike that of a normal male elephant (Fig. 3).

The dissociation of the animal from a group also pointed towards the animal being a male. The animal was under observation after relocation at Mudumalai and it continued to stay alone without joining any herd in the region. It was seen at Coonoor range, the original place from where it was removed, a year after.

Karyotyping of metaphase spreads from blood lymphocyte culture revealed 56 paired chromosomes, with an XX chromosome complement (Fig. 4). The elephant was thus determined to be a genetic female with partial masculinization, suggestive of female pseudo-hermaphroditism.

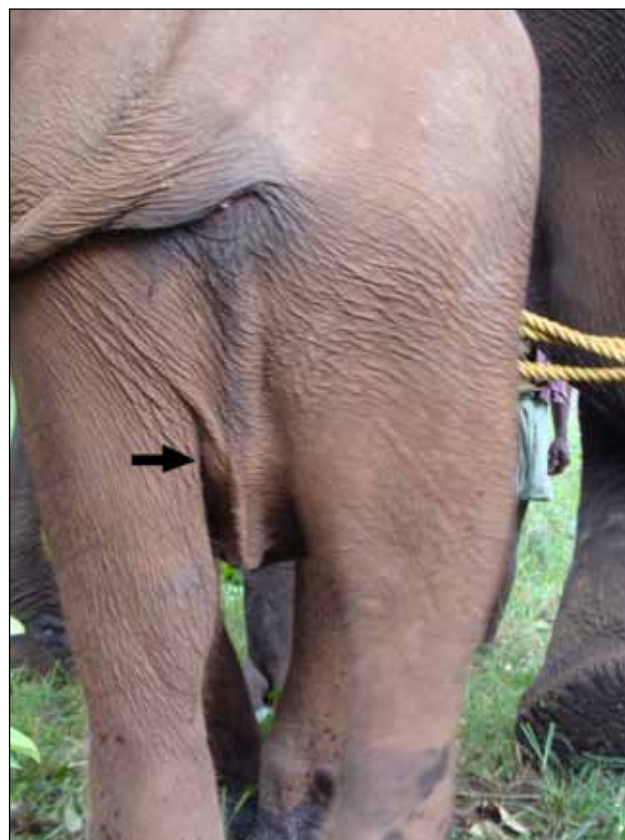

Figure 2. The features of the 'tusker' showing deviations from a normal female, the presence of a non-prominent penile cord (arrow).



Figure 3. The feminine appearance of the ‘tusker’ when compared to normal kumkhi tuskers. Note the less prominent muscles at the commisures of tusk, narrow base of the trunk and less pronounced frontal bump.

Acknowledgements

The authors are thankful to Dr. K. Narayanan, Senior Scientist, IVRI, Izatnagar for his valuable suggestions to improve the manuscript.

References

Chandrasekharan K (2002) Elephant: an overview. *Journal of Indian Veterinary Association, Kerala* 7 (special issue: Asian elephant): 8-11.

Desai AA & Johnsingh AJT (1995) Social organization and reproductive strategy of the male Asian elephant (*Elephas maximus*). Abstract in: Daniel JC & Datye HS (eds) *A Week with Elephants*. Bombay Natural History Society and Oxford University Press, Bombay. pp: 532.

Glickman SE, Short RV & Renfree MB (2005) Sexual differentiation in three unconventional

mammals: Spotted hyenas, elephants and tammar wallabies. *Hormones & Behaviour* 48: 403-417.

Halnan CRE (1977) An improved technique for the preparation of chromosomes from cattle whole blood. *Research Veterinary Science* 22: 40-43.

Sukumar R (1989) *The Asian Elephant: Ecology and Management*. Cambridge University Press, Cambridge.

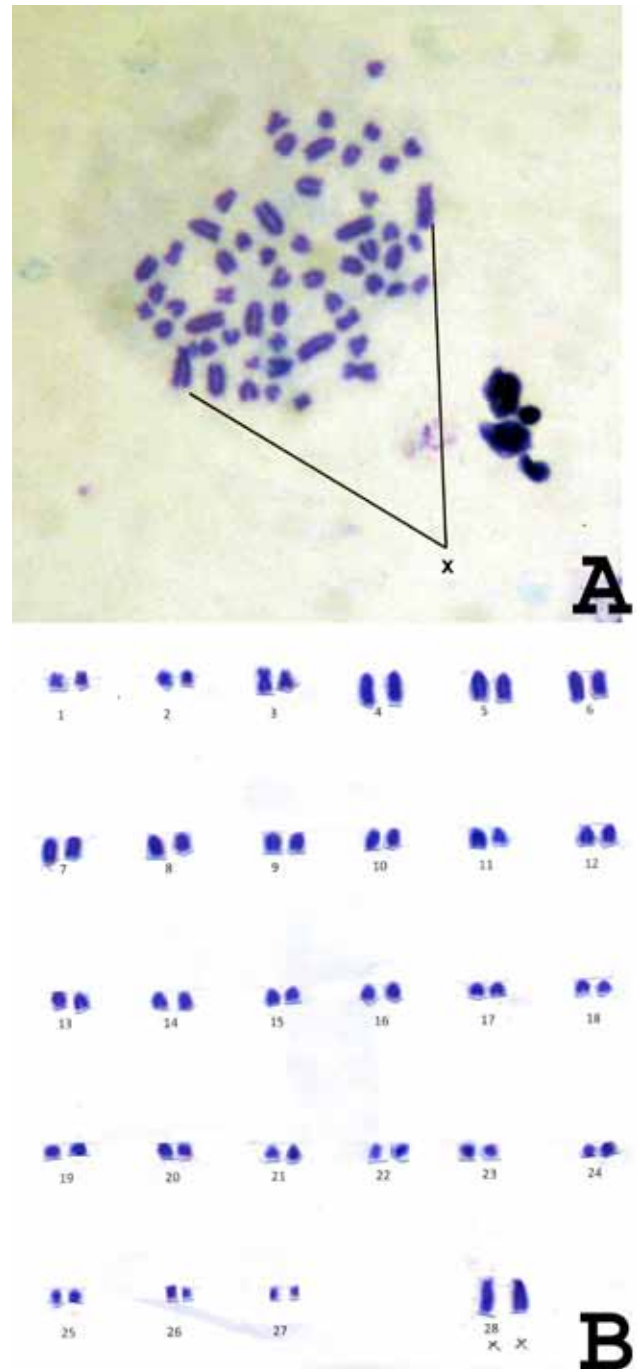


Figure 4. Metaphase spread from lymphocyte culture (a) and karyotype (56 XX) (b).