

First Confirmed Case of Fatal Tuberculosis in a Wild Sri Lankan Elephant

B. V. P. Perera^{1*}, M. A. Salgado², G. S. P. de S. Gunawardena², N. H. Smith³ and H. R. N. Jinadasa²

¹Elephant Transit Home, Department of Wildlife Conservation, Udawalawe, Sri Lanka

²Faculty of Veterinary Medicine & Animal Science, University of Peradeniya, Peradeniya, Sri Lanka.

³Animal and Plant Health Agency, Weybridge, U.K.

*Corresponding author's e-mail: vijithawildlife@gmail.com

Tuberculosis (TB) is a major emerging infectious disease among captive elephants worldwide and a potential concern for wild populations. The major causative agent for TB in elephants is *Mycobacterium tuberculosis*, which is also the primary causative agent for human TB (Fowler & Mikota 2006). Other members of the *M. tuberculosis* complex particularly *M. avium* and *M. bovis*, and non-tuberculosis mycobacteria have been associated with the infection of both African and Asian elephants (Shojaei *et al.* 2000; Payeur *et al.* 2002; Lacasse *et al.* 2007; Lyashchenko *et al.* 2015). To the best of our knowledge, no confirmed cases of TB have been reported in wild Asian elephants (*Elephas maximus*), and there are no confirmed cases reported in captive or wild Sri Lankan elephants.

An emaciated ~35-year-old female wild Sri Lankan elephant was found in a moribund state (Fig. 1) in the corridor between the Udawalawe

National Park and Lunugamwehera National Park, Sri Lanka. She was accompanied by a 1.5 year-old female calf (Fig. 1). The adult elephant died after two days of treatment with antibiotics and supportive therapy. Variable-sized multifocal to coalescing yellow-grey nodules with caseous centres affecting >60% of the lung tissue were observed during post-mortem examination. The lesions were highly suggestive of pulmonary TB (Fig. 2). Similar lesions were not observed in any other tissue.

Histopathological examination of the lung lesions revealed that the pulmonary tissue was effaced by coalescing, multiple granulomas of variable sizes (Figs. 3 & 4). These tuberculous granulomas (tubercles) contained a centre of caseous necrosis and peripheral fibroplasia with a granulomatous inflammatory reaction characterized by the presence of macrophages, epithelioid cells, lymphocytes and plasma



Figure 1. The elephant at presentation, immediately after the initiation of I/V fluids.

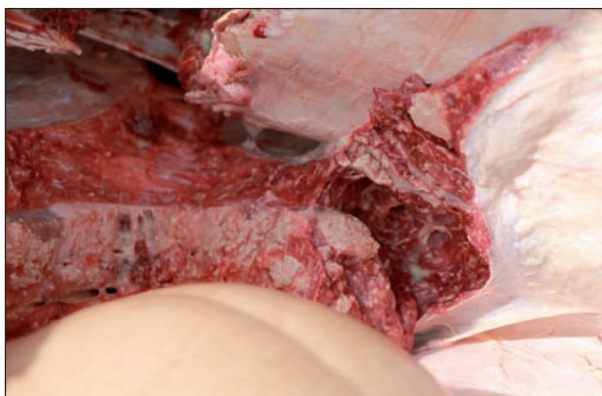

Figure 2. Gross pathology of the lungs showing several variably sized multifocal to coalescing yellow-grey nodules with caseous centres.

cells, further supporting the gross pathological observations of pulmonary tuberculosis.

A pure culture of acid fast bacilli was isolated on Lowenstein-Jensen (LJ) medium with glycerol, from the lung lesions approximately three weeks post inoculation (Fig. 5). The isolate also grew on LJ medium with sodium pyruvate, but at a slower rate. Glycerol enhances the growth of *M. tuberculosis* while it is inhibitory to *M. bovis*. Added sodium pyruvate has no effect on the growth of *M. tuberculosis* but enhances the growth of *M. bovis* (Quinn *et al.* 2011). No other bacteria or fungi were recovered on conventional media.

Since routine biochemical identification of acid fast bacilli is time consuming, molecular methods were used to identify the isolate. Due to a very high degree of conservation in housekeeping

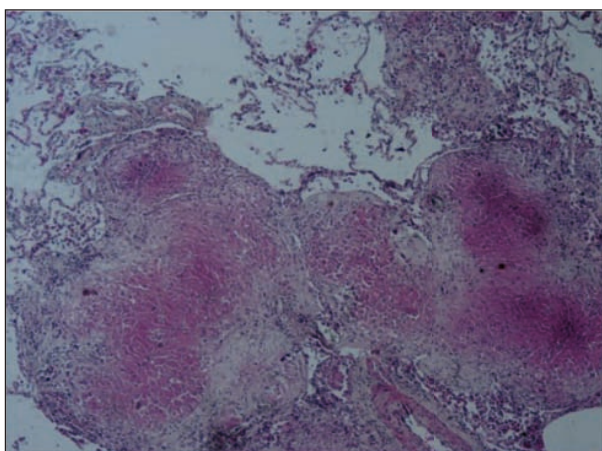


Figure 3. Histological section of the lung lesion showing multiple, coalescing, tuberculous granulomas (H&E, X40).

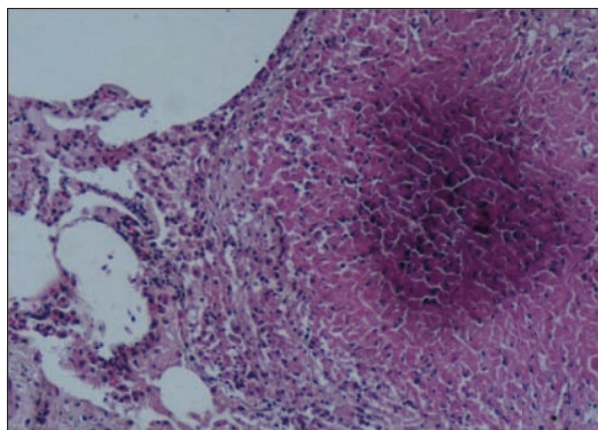


Figure 4. Caseonecrotic centre of the tuberculous granuloma is encircled mainly by epithelioid cells and macrophages. Infiltration of lymphocytes, plasma cells and proliferation of fibrous tissue are seen at the periphery (H&E, X100).

genes among the members of *M. tuberculosis* complex, the presence or absence of variable regions in the *Mycobacterium* genome known as genomic Regions of Difference (RD) are used as markers for molecular identification (Brosch *et al.* 2002). Accordingly, PCR was performed to detect the presence or absence of RD9 as described by Brosch *et al.* (2002). The RD9 is present only in *M. tuberculosis* except in the rare isolates of “*M. canettii*”, which were reported only in humans from East Africa and France (van Soolingen *et al.* 1997; Brosch *et al.* 2002). Reference culture DNA of *M. tuberculosis* and *M. bovis* obtained from Animal and Plant Health Agency, Weybridge, UK was used as controls.

The PCR results for this isolate demonstrated the presence of an intact RD9 (Fig. 6), strongly suggesting the isolate was *M. tuberculosis*. The presence of clear bands corresponding to 364

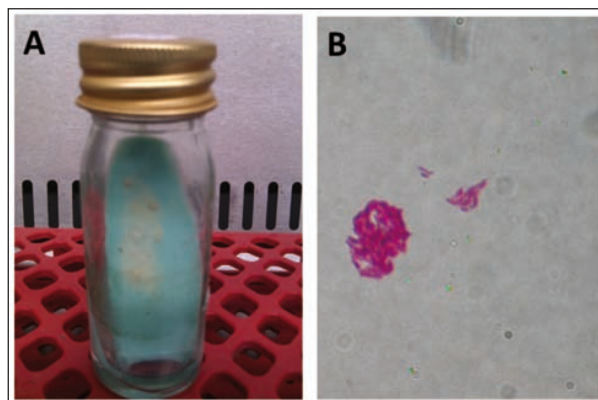


Figure 5. Culture on LJ medium (A) and acid fast bacilli (B).

bp in the RD9 internal PCR (lanes 1 & 2) and absence of bands in the RD9 flanking PCR (lanes 1 & 2) demonstrate the presence of an intact RD9 (Brosch *et al.* 2002). No bands are visible with the flanking primers because the product generated by an intact RD9 is 2.5 kb, and thus not visualized (Brosch *et al.* 2002). In contrast, strains that lack RD9 (such as *M. bovis*, used as a control here) generate a smaller product of 472 bp (Brosch *et al.* 2002). *M. canettii* the only other member of the *M. tuberculosis* complex having an intact RD9 has clearly different colony morphology in primary isolates compared to *M. tuberculosis* (van Soolingen *et al.* 1997). Therefore, the presence of an intact RD9 and growth characteristics of this *Mycobacterium* isolate confirm its identity as *M. tuberculosis*.

Numerous cases of TB have been reported in captive Asian elephants (Mikota *et al.* 2001; Dumonceaux *et al.* 2011; Ong *et al.* 2013). There is also evidence that TB can be transmitted between elephants and humans (Oh *et al.* 2002; Murphree *et al.* 2011). In one case, an elephant and handler with active TB shared the same strain but the direction of transmission (elephant to human or human to elephant) was not determined (Michalak *et al.* 1998). Acid fast bacilli were observed in lung tissue from a wild African elephant that had a history of human contact and died from a suspected *M. tuberculosis* infection (Obanda *et al.* 2013).

Our report is the first confirmed case of fatal TB in a wild Asian elephant, and also the first confirmed case of TB in a captive or wild Sri Lankan elephant. The source of infection for this elephant is unknown as no information was available on its human contacts if any, and there are no known wild reservoirs of *M. tuberculosis* in Sri Lanka. This case demonstrates that Asian elephants can be infected with *M. tuberculosis* in the wild, and develop fatal tuberculosis.

Acknowledgements

The authors thank Dr. Susan Mikota (Elephant Care International, USA) for thoughtful comments and Prof. Vasanthi Thevanesam, Dr. Champa Ratnatunga (University of Peradeniya, Sri Lanka) and Dr. Dhammika Magana-Arachchi (Institute of Fundamental Studies, Sri Lanka) for consultations and training laboratory personnel. Mr. Sampath Bandara and Mrs. Waruni Jayaweera (University of Peradeniya, Sri Lanka) provided technical assistance.

References

Brosch R, Gordon SV, Marmiesse M, Brodin P, Buchrieser C, Eiglmeier K, Garnier T, Gutierrez C, Hewinson G, Kremer K, Parsons LM, Pym AS, Samper S, van Soolingen D & Cole ST (2002) A new evolutionary scenario for the *Mycobacterium tuberculosis* complex. *PNAS* **99**: 3684-3689.

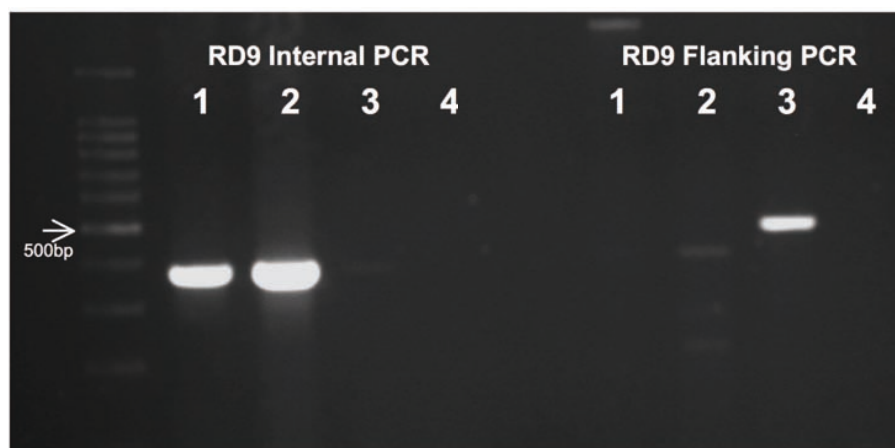


Figure 6. Ethidium bromide stained agarose gel image of PCR results for RD9. The presence of clear bands at 364 bp level in RD9 internal PCR (lanes 1 & 2) and absence of bands in RD9 flanking PCR (lanes 1 & 2) demonstrates the presence of intact RD9 region. Lane 1 = DNA from *Mycobacterium* isolate, lane 2 = *M. tuberculosis* (H37Rv) reference DNA, lane 3 = *M. bovis* (61/2122/97) reference DNA, lane 4 = negative control.

- Dumonceaux GA, St Leger J, Olsen JH, Burton MS, Ashkin D & Maslow JN (2011) Genitourinary and pulmonary multidrug resistant *Mycobacterium tuberculosis* infection in an Asian elephant (*Elephas maximus*). *Journal of Zoo and Wildlife Medicine* **42**: 709-712.
- Fowler ME & Mikota SK (2006) *Biology, Medicine and Surgery of Elephants*. Blackwell, USA.
- Lacasse C, Terio K, Kinsel MJ, Farina LL, Travis DA, Greenwald R, Lyashchenko KP, Miller M & Gamble K (2007) Two cases of atypical mycobacteriosis caused by *Mycobacterium szulgai* associated with mortality in captive African elephants (*Loxodonta africana*). *Journal of Zoo and Wildlife Medicine* **38**: 101-107.
- Lyashchenko KP, Greenwald R, Esfandiari J, Olsen JH, Ball R, Dumonceaux G, Dunker F, Buckley C, Richard M, Murray S, Payeur JB, Andersen P, Pollock JM, Mikota S, Miller M, Sofranko D & Waters WR (2015) Tuberculosis in elephants: Antibody responses to defined antigens of *Mycobacterium tuberculosis*, potential for early diagnosis, and monitoring of treatment. *Clinical and Vaccine Immunology* **13**: 722-732.
- Michalak K, Austin C, Diesel S, Bacon JM, Zimmerman P & Maslow JN (1998) *Mycobacterium tuberculosis* infection as a zoonotic disease: Transmission between humans and elephants. *Emerging Infect. Diseases* **4**: 2.
- Mikota SK, Peddie L, Peddie J, Isaza R, Dunker F, West G, Lindsay W, Larsen RS, Salman MD, Chatterjee D, Payeur J, Whipple D, Thoen C, Davis DS, Sedgwick C, Montali R, Ziccardi M & Maslow J (2001) Epidemiology and diagnosis of *Mycobacterium tuberculosis* in captive Asian elephants (*Elephas maximus*). *Journal of Zoo and Wildlife Medicine* **32**: 1-16.
- Murphree R, Warkentin JV, Dunn JR, Schaffner W & Jones TF (2011) Elephant-to-human transmission of tuberculosis, 2009. *Emerging Infectious Diseases* **17**: 366-371.
- Obanda V, Poghon J, Yongo M, Mulei I, Ngotho M, Waititu K, Makumi J, Gakuya F, Omondi P, Soriguer RC & Alasaad S (2013) First reported case of fatal tuberculosis in a wild African elephant with past human-wildlife contact. *Epidemiology & Infection* **141**: 1476-1480.
- Oh P, Granich R, Scott J, Sun B, Joseph M, Stringfield C, Thisdell S, Staley J, Workman-Malcolm D, Borenstein L, Lehnkering E, Ryan P, Soukup J, Nitta A & Flood J (2002) Human exposure following *Mycobacterium tuberculosis* infection of multiple animal species in a Metropolitan Zoo. *Emerging Infectious Diseases* **8**: 1290-129.
- Ong BL, Ngeow YF, Razak MF, Yakuba Y, Zakaria Z, Mutalib AR, Hassan L, Ng HF & Versahib K (2013) Tuberculosis in captive Asian elephants (*Elephas maximus*) in Peninsular Malaysia. *Epidemiology and Infection* **141**: 1481-1487.
- Payeur JB, Jarnagin JL, Marquardt, JG & Whipple DL (2002) *Mycobacterium* isolation in captive elephants in USA. *Annals of New York Academy of Sciences* **969**: 256-258.
- Quinn PJ, Markey BK, Leonard FC, Hartigan P, Fanning S & FitzPatrick ES (2011) *Veterinary Microbiology and Microbial Disease*. 2nd Edition. Wiley-Blackwell, USA.
- Shojaei H, Magee JG, Freeman R, Yates M, Horadagoda NU & Goodfellow M (2000) *Mycobacterium elephantis* sp. nov., a rapidly growing non-chromogenic *Mycobacterium* isolated from an elephant. *International Journal of Systematic and Evolutionary Microbiology* **50**: 1817-1820.
- van Soolingen D, Hoogenboezem T, de Haas PE, Hermans PW, Koedam MA, Teppema KS, Brennan PJ, Besra GS, Portaels F, Top J, Schouls LM & van Embden JD (1997) A novel pathogenic taxon of the *Mycobacterium tuberculosis* complex, Canetti: characterization of an exceptional isolate from Africa. *International Journal of Systemic Bacteriology* **47**: 1236-1245.